

# An Unforeseen Presentation: Dengue And Chikungunya Coinfection Associated With Multi Organ Dysfunction Syndrome And Ttp: A Case Report.

Likitha

## Corresponding author

Likitha ,

Bangalore, India.

Email : likithabs1001@gmail.com

**Received Date:** December 14, 2024

**Accepted Date:** December 15, 2024

**Published Date:** January 25, 2024

**Copyright** © 2024 Likitha. This is an open access article distributed under the Creative Commons Attribution License, which permits unrestricted use, distribution, and reproduction in any medium, provided the original work is properly cited.

## ABSTRACT

Dengue (DENV) and chikungunya (CHIKV) fever are the two serious arboviral diseases presenting as self-limiting acute febrile illness reporting over 1,00,000 cases in a year. Here we discuss a case of dengue and chikungunya coinfection associated with Thrombotic Thrombocytopenic Purpura (TTP) in an adult Indian female presented with acute febrile illness that later on progressed to Multi Organ Dysfunction Syndrome affecting brain, kidney, lungs and haematological system. We discuss the diagnostic approaches, management of this complicated case and would like to generate an awareness regarding the coinfection of these viruses, their complications leading to multiorgan damage.

**Keywords:** Dengue fever, Thrombocytopenia, Chikungunya virus, Thrombotic Thrombocytopenic Purpura, Multi Organ Dysfunction Syndrome, Coinfection

## INTRODUCTION

Dengue (DENV) and chikungunya (CHIKV) fever are the two serious arboviral diseases presenting as self-limiting acute febrile illness reporting over 1,00,000 cases in a year. Since CHIKV-affected and DENV-endemic regions of Asia overlap, mosquitoes can carry both diseases. The indications and symptoms of both conditions are the same, including fever, chills, swelling in the major and minor joints with pain,

difficulty in moving limbs, nausea, headache, vomiting, and the development of rashes<sup>1</sup>. Owing to their similar symptoms, dengue and chikungunya virus present as coinfection with fatality rates approximately 0.5–3.5% and 0.1%, respectively<sup>2</sup>. Dengue fever (DF) is a viral illness caused by a flavivirus having four antigenic serotypes, known as DENV-1, DENV-2, DENV-3, and DENV-4. The disease spectrum varies from mild cases of dengue fever (DF) to more severe cases of dengue haemorrhagic fever (DHF) or dengue shock syndrome<sup>3</sup>.

Chikungunya is an acute, subacute or chronic illness presenting with acute fever, myalgia, headache, rash, and arthralgia which lasts up to 3 weeks. In certain cases of CHIK, painful polyarthralgia and polyarthritis may last for months or even years. Similar to what is seen during dengue outbreaks, the case-fatality ratio (CFR) for CHIK in La Reunion, Southeast Asia, and Brazil has been estimated to be between 1 and 1.3 deaths per 1,000 cases. CHIK fatalities were more common in older adults and infants and were linked to sepsis and irreversible multiple organ dysfunction syndrome<sup>4</sup>.

TTP, or thrombotic thrombocytopenic purpura, is a rare blood condition. Thrombi, or blood clots, form in the tiny blood vessels all over your body when you have TTP. The heart, kidneys, and brain are among the essential organs of your body that may experience blood flow restriction due to these thrombi. TTP is hallmarked by dysfunctional ADAMTS 13 activity which is essential in controlling the coagulation cascade because it has the ability to reduce the amount of von Willebrand factor (vWF) in the blood. Ultimately leading to subsequent microthrombi development and platelet activation that obstruct the systemic microvasculature, which is essential to the majority of main organ functions. Although survival rates have significantly increased since plasmapheresis was introduced, the death rate for patients receiving standard care still ranges from 7% to 22%<sup>6</sup>.

As both dengue and chikungunya fever can transmit through the same vector and share similar symptoms, ruling out the diagnosis and its timely management could be time consuming. Here we discuss a case with dengue and chikungunya coinfection, ruling out the exact causes, its diagnosis and treatment approaches followed.

# Clinical Imaging and Case Reports (ISSN 2770-9205)

## CASE PRESENTATION

A 53-year-old Indian female of nil comorbidities presented to our outpatient clinic with pyrexia of unknown origin accompanied by headache, cough with expectoration, vomiting, loose stools and generalised weakness. On admission, she was afebrile and hypotensive and hence fluid bolus given. Upon examination, she was conscious and oriented, dehydrated, and tenderness was noted in the epigastric and hypogastric region. The patient was investigated for the common causes and reports on day 1 (Table 1,2) were suggestive of dengue fever with thrombocytopenia (Ns1 and IgG) and acute kidney injury. She was persistently hypotensive (70/40 mm Hg) with low platelet count (12k), drowsy and oliguria, therefore shifted to MICU and started on inotropic support. Fever syndromic panel revealed positive for chikungunya virus and dengue.

**Table 1:** Serological workup of the patient from Day 1 to Day 14

Lab Parameters (Normal Range)	D1	D2	D3	D4	D7	D8	D9	D10	D11	D12
Serum creatinine (0.7-1.2 mg/dl)	3.03	3.6	4.26	4.18	2.65	1.84	1.31		0.73	0.69
ALP (<98 U/L)	172							213		
SGOT (<32 U/L)	597	419						274		
SGPT (< 33U/L)	245	185						113		
Bilirubin -Total	2.64									
NT-PRO BNP						6611				
Troponin-I (0-29ng/L)						244.8				
Prothrombin time (11.5-16 secs)				17.1				11.6		
INR (0.8-1.2)				1.24				0.79		
APTT (24.4-37.2 secs)				97.9				32.1		
LDH (<480 U/L)								1350		

D: Day; WBC: White Blood Cell; ALP: Alkaline Phosphatase; SGOT: serum glutamate oxaloacetate transaminase; SGPT: serum glutamate pyruvate transaminase; INR: International Normalised Ratio; APTT: Activated Partial Thromboplastin Time; LDH: Lactate Dehydrogenase.

**Table 2:** Other laboratory reports

Test	Result
Dengue NS1 antigen	Positive
Anti-dengue IgM	Positive
Anti-dengue IgG	Negative
Chikungunya virus	Positive
Widal slide agglutination test	Negative
Blood smear examination	Schistocytes present
Direct Coombs Test	Negative
ADAM TS 13	< 27%

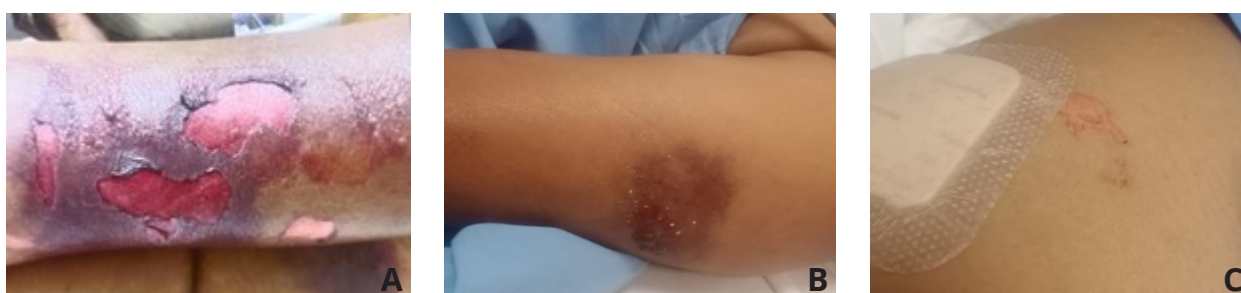On early morning of day 3, she had 1 episode of generalised clonic-tonic seizure (GTCS) associated with tongue bite and excessive oral bleed. In view of persistent platelet drop and active bleeding due to tongue bite, platelet transfusion (6RDPs and 2SDPs) was done. CT-brain revealed no acute changes. She was added with intravenous levetiracetam 500mg (10mg/kg), post seizure episode. As her condition was improving, she was shifted to ward. In view of persistent platelet drop, 1 unit SDP transfusion was done and started with STAT dose of intravenous romiplostin 250mcg (1mcg/kg). Oral care was given on regular basis by cleaning with normal saline, intravenous metronidazole(7.5mg/kg) and oral glycerine. Blisters and erosions over both arms and thighs (figure1) were observed and treated with sodium fucidate ointment. Patient position was changed frequently to prevent damage to the skin. By early night on day 8, patient developed sudden onset of chills and her saturation dropped to 80% at 10L oxygen via non-rebreather mask. Suspecting pulmonary edema, CT thorax + upper abdomen was performed which revealed bilateral mild to moderate pleural effusion with passive collapse of bilateral lower lobes, few patchy areas of ground glass opacities in upper and middle lobes along with bulky kidneys suggesting pyelonephritis. Urine culture revealed

## Clinical Imaging and Case Reports (ISSN 2770-9205)

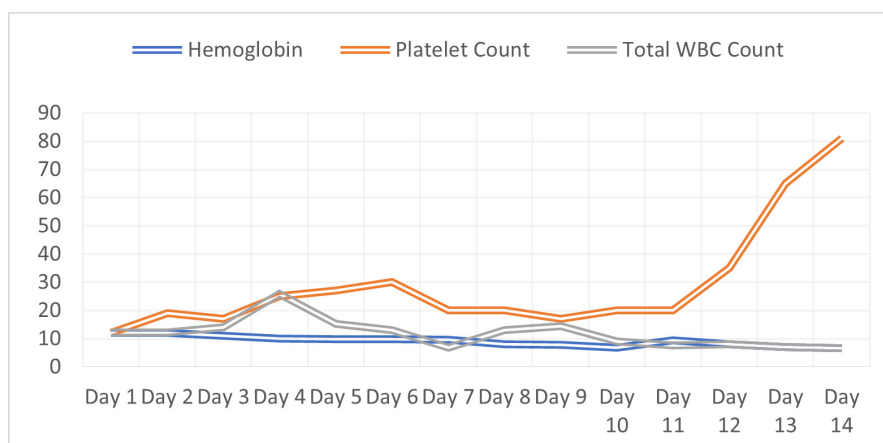
isolates of *E. coli* and hence started with intravenous meropenem(20mg/kg). Peripheral blood smear examination revealed presence of schistocytes.

In view of positive schistocytes, haemolysis workup and direct coombs test was suggested. Direct coombs test proved to be negative. Positive occult blood for stool suspected that melena could be secondary to underlying platelet count and bicytopenia is secondary to possible HLH/TTP. Taking note of persistent thrombocytopenia with signs of haemolysis, she was clinically diagnosed with TTP and started with intravenous methyl prednisolone 1gm for 3 days (pulse steroid therapy) followed by 1mg/kg of methyl prednisolone along with plasma exchange daily for 3 days. As the patient overall condition and blood parameters improved; she was mobilised and shifted to the ward. Patient was advised for two more cycles of plasma exchange followed by oral prednisolone 40mg twice a day. She was then added with oral aspirin 75mg once a day when her platelet count reached 75k. Vitals and lab parameters were monitored regularly in the wards. As the patient improved symptomatically and was hemodynamically stable, patient was discharged with oral antibiotic and oral steroid. She received 3pint PRBC transfusion and around 56 FFPs in total.

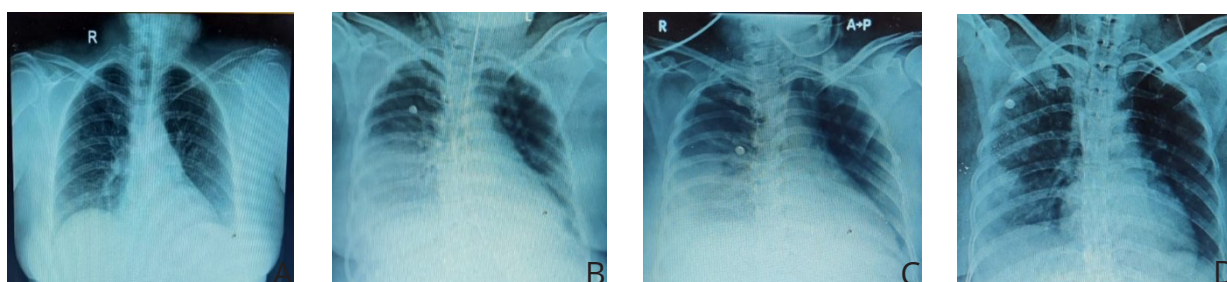
**Figure 1:** Blisters and erosions seen on the patient's right arm (A), left arm (B) and left inner thigh (C)



**Figure 2:** Lab workup of the patient from Day 1



**Figure 3:** Chest X-ray radiographs from Day 1 to Day 14



(A) Day 1: No Significant Abnormality; (B) Day 4: Patch Opacity In Right Lower Zone; (C) Day 9: Patchy Opacities In Right Lower Zone Resolving; (D) Day 10: Resolution Of Opacities

# Clinical Imaging and Case Reports (ISSN 2770-9205)

## DISCUSSION

RNA viruses called DENV and CHIKV are spread among individuals via Aedes mosquito bites. Studies on vector competence have demonstrated that specific mosquito species are capable of supporting simultaneous transmission of both viruses. Consequently, bites from co-infected mosquitoes (co-illnesses) or consecutive bites from mono-infected mosquitoes (superinfection) can result in human DENV-CHIKV infections. Viral co-infections have complicated dynamics; like direct interactions between the infecting viruses, changes to the host's sensitivity and cellular translation, and adjustments to the host immune system and many more. It's crucial to take into account the time of each infection, especially if the host is affected by superinfection or co-infection<sup>7</sup>. Here in our case, we observe a patient coinfecting with dengue and chikungunya virus which later on led to the complications and multiorgan damage syndrome (acute kidney injury and urosepsis). Additionally, coinfection with persistent thrombocytopenia led to diagnose thrombotic thrombocytopenic purpura.

Here in our case, patient was maintaining persistent low platelet counts in spite of numerous platelet transfusions. Ruling out the exact cause for persistent thrombocytopenia in addition to dengue chikungunya coinfection was quite challenging. Significant low blood workup raised a suspicion for haemolysis and hence necessary work up was made. Decreased ADAM TS13 led us to suspect our case clinically as thrombotic thrombocytopenic purpura (TTP). Treating TTP requires an early onset of plasma exchange; however, distinguishing TTP from DIC, haemolytic uremic syndrome (HUS), and heparin-induced thrombocytopenia (HIT) can be difficult. Because coagulation is typically intact in TPP, it may be possible to distinguish TTP from DIC in some circumstances by looking for normal fibrin degradation product (FDP), PT, and PTT levels. TTP can be verified by additional laboratory testing that measure anti-ADAMTS13 antibodies and ADAMTS13 activity.

## CONCLUSION

Although coinfection of DENV and CHIKV is more commonly reported in India, some reports suggests that neither the presentation nor clinical progress become worsen due to coinfection whereas some reports indicate a high proportion of severe symptoms and poor clinical outcome among coinfecting individuals. These different opinions highlight the need to understand the impact of coinfection and its outcome and complications.

Early diagnosis for TTP at right time could pave way for proper treatment selection and survival rate. Thrombocytopenia in patients would primarily mislead in confirming the diagnosis.

Although the clinical presentation of immune thrombotic thrombocytopenic purpura (iTTP) varies greatly between patients, the condition's early diagnosis can be difficult due to its frequently broad symptoms that overlap with those of other thrombotic microangiopathies.

This case highlights that thrombotic disorders should also be kept in mind and correlate with the provisional diagnosis made when the patient doesn't improve for the treatment prioritised. It also highlights the importance of suspecting and correlating various parameters for the better outcome of the patient.

## REFERENCES

1. Hashim et al. Clinico Microbiological Profile of Dengue and Chikungunya Co-Infections in Patients Attending a Tertiary Care Hospital, Siddipet. *International Journal of Toxicological and Pharmacological Research* 2024; 14(5): 75-79
2. Ahmad Adebayo Irekeola et al. Global prevalence of dengue and chikungunya coinfection: A systematic review and meta-analysis of 43,341 participants. *Acta Tropica*. July 2022; Volume 231,106408 <https://doi.org/10.1016/j.actatropica.2022.106408>
3. Kaur M, Singh K, Sidhu SK, Devi P, Kaur M, Soneja S, et al. Coinfection of chikungunya and dengue viruses: A serological study from North Western region of Punjab, India. *J Lab Physicians*. 2018;10:443-7
4. William M. de Souza et al, Pathophysiology of chikungunya virus infection associated with fatal outcomes. *Cell Host & Microbe*. 2024;32,606-622. <https://doi.org/10.1016/j.chom.2024.02.011>
5. Taraphdar D, Singh B, Pattanayak S, Kiran A, Kokavalla P, Alam MF and Syed GH. Comodulation of Dengue and Chikungunya Virus Infection During a Coinfection Scenario in Human Cell Lines. *Front. Cell. Infect. Microbiol*. 2022; 12:821061. <https://doi.org/10.3389/fcimb.2022.821061>
6. Sea JL, Gassner SF, Smart J. Case Report of Thrombotic Thrombocytopenic Purpura in a Previously Healthy Adult. *J Educ Teach Emerg Med*. 2021 Jan 15;6(1): V1-V4. doi: 10.21980/J8VK9M.
7. Zaidi, M.B., Garcia-Cordero, J., Rivero-Gomez, R. et al. Competitive suppression of dengue virus replication occurs in chikungunya and dengue co-infected Mexican infants. *Parasites Vectors*. 2018; 11: 378. <https://doi.org/10.1186/s13071-018-2942-1>